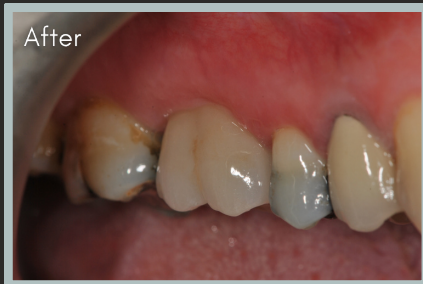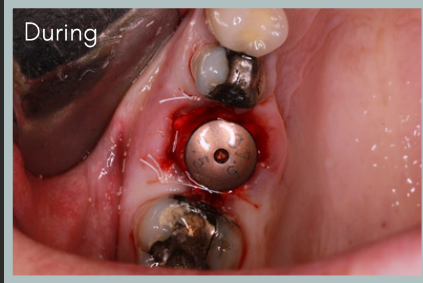

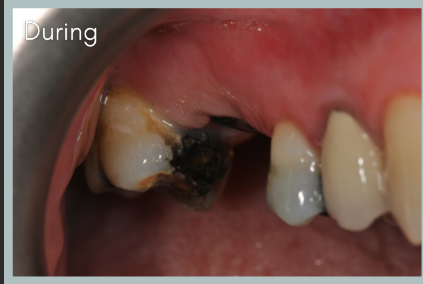
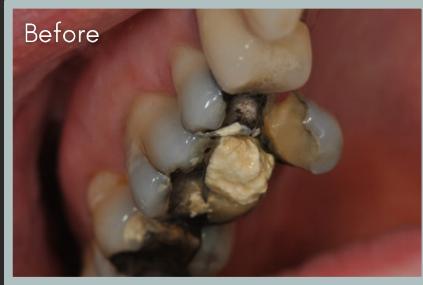# Dental Implants by Haytham Abbas



## BROKEN UPPER RIGHT 1ST MOLAR TOOTH

### PATIENT CONCERNS

The patient presented complaining of a fractured tooth making it difficult to chew on the right side.

### PATIENT TREATMENT GOALS

To be able to comfortably chew on the right side of their mouth again.

### DIAGNOSIS

- Fractured and unrestorable upper right 1st molar
- All options discussed with patient opting for implant.
- Confirmed suitable for immediate implant treatment

### TREATMENT COMPLETED

- ✓ CT scan was taken to assess the bone volume and suitability for implant treatment.
- ✓ Tooth was extracted and an implant placed immediately along with a synthetic bone graft.
- ✓ Healing abutment placed along with two sutures, which were removed after two weeks of healing.
- ✓ Impressions for crown taken three months after implant placement.
- ✓ Crown fitted two weeks after impressions.

To refer a case to Haytham, please use the contact details below

**Vitality Dental Care Fairfield**  
Wellburn Road, Fairfield, Stockton-on-Tees, TS19 7PP  
01642 587646  
vfreception@riverdalehealthcare.com

